(Acta Anaesth. Belg., 2017, 68, 49-62)

# A Qualitative Systematic Review of the Pectoral Nerves Block Type I and II

B. Versyck (*), P. Van Houwe (**), G. J. van Geffen, M. Van de Velde (*) and R. Slappendel (***)

**Summary** : The pectoral nerves (Pecs) blocks are challenging the conventional approach of basing change in practice on scientific evidence. Indeed, several practitioners have already incorporated these blocks into their practice before conclusive evidence regarding their efficacy and safety has been published. This systematic literature review examines the analgesic efficacy of Pecs type I and II blocks for their current indications. We searched publications indexed by MEDLINE, EMBASE, Cochrane Library and Google Scholar from inception to October 2016 without publication type, status, language or publication period restrictions. In addition, we searched references and citations for other relevant studies. Results from our systematic literature search show encouraging and consistent evidence that the Pecs blocks produce effective analgesia, and reduce perioperative opioid consumption as compared to control groups without regional anesthesia, as well as other regional anesthesia techniques. Furthermore, the Pecs blocks provide favorable analgesic results in a wide range of indications including regional anesthesia and pain medicine technique. The absence of block-related complications reported in the literature may suggest that the Pecs blocks are easy to apply and safe for patients.

**Key words** : Pecs block, Pectoral Nerves block, Thoracic Wall Block, Breast Surgery, Analgesia, Regional Anesthesia

Regional anesthesia is becoming an essential component of modern multimodal analgesia for many types of surgeries. It can improve patient outcomes in terms of acute and persistent postsurgical pain, and can enhance recovery (1). Since 2011, Blanco and his colleagues (2, 3) described two new ultrasound-guided thoracic wall blocks. First, they (2) described a technique to inject local anesthetic agents in between the pectoralis major and minor muscles, which they successfully performed in 50 patients requiring analgesia after breast surgery. One year later, Blanco *et al*. (3) described a modified version of this technique where they additionally injected local anesthetic agents between the pectoralis minor and serratus muscle. Upon introduction of the second block, Blanco *et al*. (3) labeled the first block the Pecs I (pectoral nerve block type I) and the second technique Pecs II. The Pecs I block aims at providing analgesia for breast surgery by blocking the medial and lateral pectoral nerves (3,4). Pecs II additionally blocks the axilla by targeting at least the intercostobrachial, III-VI intercostals, and the long thoracic nerves (3,4) Figures 1 and 2 summarize the relevant anatomy for these techniques, the positioning of the ultrasound probe and the corresponding ultrasound image.

The Pecs blocks are presented as practical alternatives to the paravertebral and thoracic epidural block for breast surgery. Compared to these blocks, the Pecs blocks are suggested to be both simple and reliable (2,3). As with any new technique, it is required to justify the adoption of the technique based on enhanced patient safety and improved cost-benefit compared to current practices. We hypothesized that adult patients undergoing breast surgery with the Pecs blocks have improved analgesia as compared to patients without regional anesthesia or with other regional anesthesia techniques. We also hypothesized that the Pecs blocks can be applied for a wide range of clinical indications. Therefore, this systematic review aims at reviewing the current indications and evidence of the two blocks. Finally, we propose directions for future research.

## Methods

A systematic review of the medical literature in accordance to the PRISMA Statement Guidelines

Barbara Versyck, M.D. ; Patrick Van Houwe, M.D. ; Geert Jan van Geffen, M.D., PhD., EDRA ; Marc Van de Velde M.D., PhD., EDRA; Robert Slappendel M.D., PhD. ;
(*) University Hospitals Leuven Herestraat 49, 3000 Leuven (Belgium).
(**) GZA Sint-Augustinus Hospital, Oosterveldlaan 24, 2610 Wilrijk (Belgium).
(***) University of Antwerp, Prinsenstraat 13, 2000 Antwerpen (Belgium).
**Correspondence address** : Barbara Versyck, University Hospitals Leuven, Herestraat 49, 3000 Leuven (Belgium). Tel: +32 16 344270
E-mail : barbaraversyck@hotmail.com

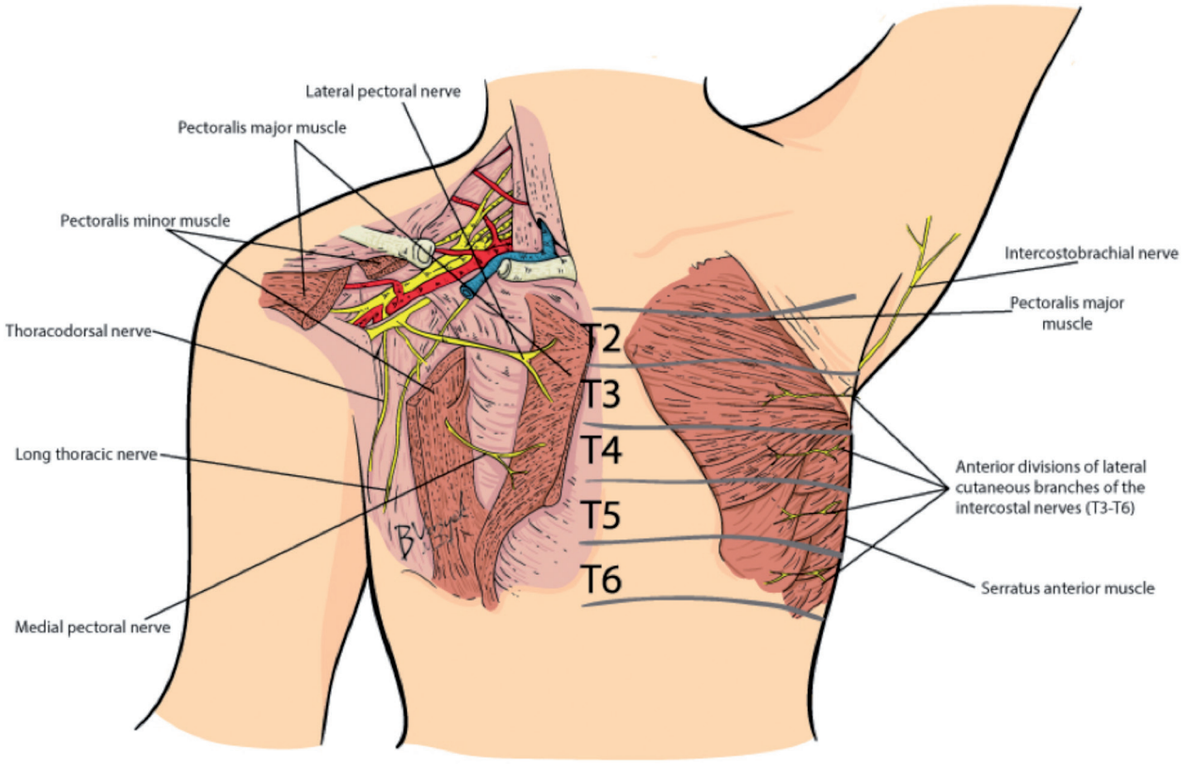


Fig. 1. — Relevant anatomy for the Pecs blocks : nerves and muscles (right hemithorax : nerves from brachial plexus, left hemithorax : thoracic spinal nerves).

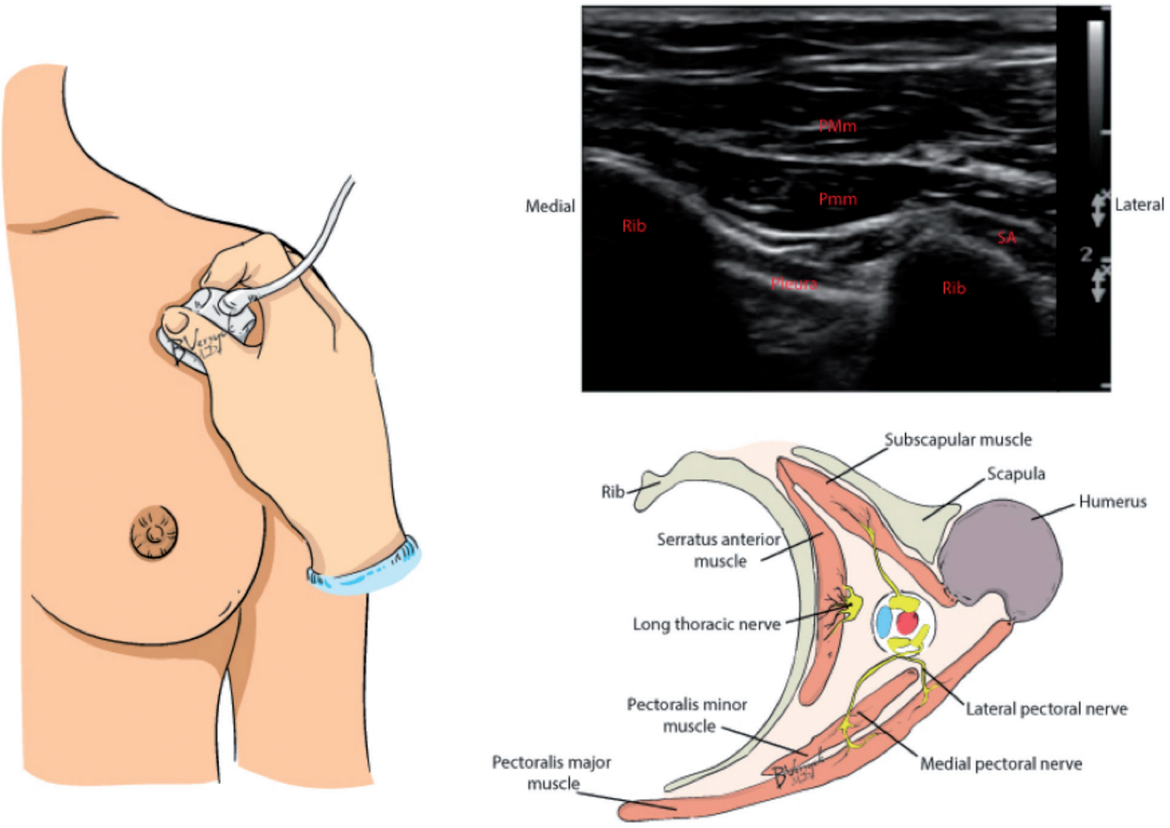


Fig. 2. — Positioning of ultrasound probe and the corresponding ultrasound image and cross-sectional anatomy.

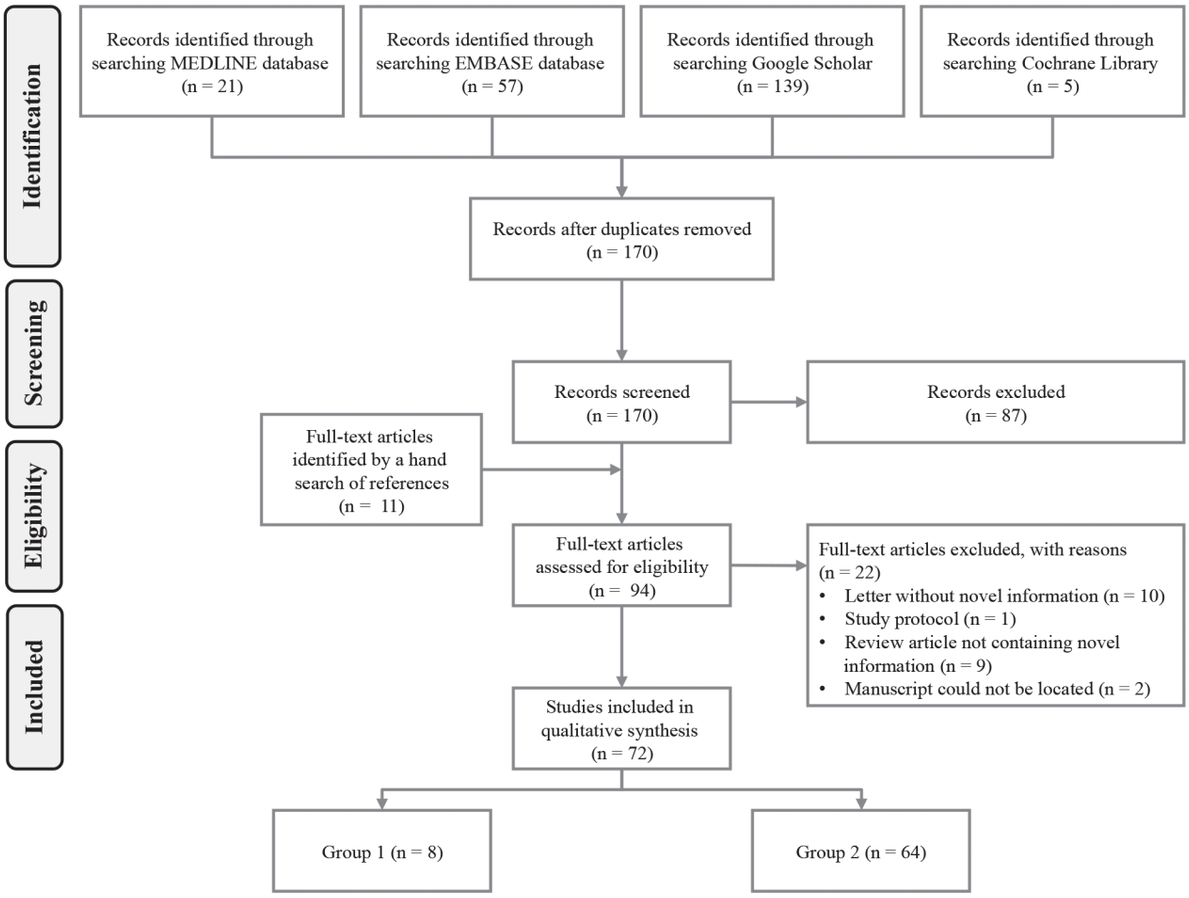


Fig. 3. — PRISMA flow diagram.

(5) (Preferred Reporting Items for Systematic Reviews and Meta-analyses) was performed for the identification, screening, and inclusion of articles (Fig. 3). A review protocol was written before conducting this study and published on PROSPERO, a prospective register of systematic reviews, with identifier 42016047568. The study search was conducted on October 8th, 2016 by one of the authors (B.V.). Articles indexed by MEDLINE, EMBASE, Cochrane Library or Google Scholar were included in this review. Search terms included the free text words: "Pecs block" OR "pectoral nerve block" OR "pectoral nerves block". We applied no publication type, status, language or publication period restrictions in the searches. In addition, we searched references and citations for other relevant studies. The management of this review was performed with the Covidence software.

Studies were allocated to one of two groups. Group 1 contained full articles of randomized controlled trials (RCTs), non-randomized controlled trials or observational studies involving at least 10 adult (age > 18 years) participants per arm to assess the block characteristics. To compare these studies, we extracted the following study data: year of publication, author(s), study design, Pecs block type assessed and its comparator, volume, concentration and type of local anesthetic agent used, type of surgery and total number of participants. Collected study results were as follows: (1) pain scores, (2) opioid consumption, (3) time to first analgesic requirement, (4) sensory block duration, (5) opioid related adverse effects (postoperative nausea and vomiting (PONV), pruritus and sedation), (6) patient satisfaction and (7) block-related complications. The pain score and opioid consumption outcomes were divided into the intra- and postoperative period, and the postoperative period was further divided into early (< 4 hrs.), mid (4-24 hrs.) and late (24-48 hrs.), if available. These data points were recorded in tables and outcomes were evaluated

Table 1. Overview of RCTs and cohort studies involving at least 10 participants per arm.

| Author/Year | Block investigated | Study design | Evidence level | Jadad or NOS score | Surgery | n | Groups (n) |
|---|---|---|---|---|---|---|---|
| BASHANDY *et al.*, 2015 (13) | Pecs II | RCT | 1b | 3 / 5 | Modified radical mastectomy | 120 | - GA (60)<br>- GA with Pecs II block (60) |
| ELDEEN, 2015 (14) | Pecs II | RCT | 1b | 2 / 5 | Unilateral conservative breast surgery without axillary clearance | 40 | - Thoracic spinal block (20)<br>- Pecs II block (20) |
| HASSN *et al.*, 2016 (20) | Pecs II | RCT | 1b | 2 / 5 | Modified radical mastectomy | 60 | - GA with placebo block (30)<br>- GA with Pecs II block (30) |
| HETTA *et al.*, 2016 (18) | Pecs II without Pecs I | RCT | 1b | 3 / 5 | Unilateral modified radical mastectomy with axillary clearance | 60 | - GA with paravertebral block (30)<br>- GA with Pecs II without Pecs I block (30) |
| KULHARI *et al.*, 2016 (19) | Pecs II | RCT | 1b | 2 / 5 | Modified radical mastectomy | 40 | - GA with paravertebral block (20)<br>- GA with Pecs II block (20) |
| MORIOKA *et al*, 2015 (15) | Pecs II | Cohort study | 2b | 6 / 9 | Unilateral total or partial mastectomy | 71 | - GA: TIVA (35)<br>- GA: TIVA with Pecs II block (36) |
| SOPENA-ZUBIRIA *et al.*, 2014 (17) | Pecs I | Cohort study | 2b | 5 / 9 | Unilateral or bilateral breast surgery with subpectoral implants | 60 | - Deep sedation with paravertebral block (30)<br>- Deep sedation with Pecs I and paravertebral block (30) |
| WAHBA *et al.*, 2013 (16) | Pecs II | RCT | 1b | 2 / 5 | Modified radical mastectomy | 60 | - Paravertebral block (30)<br>- Pecs II block (30) |

Abbreviations : GA indicates General Anesthesia ; TIVA indicates Total Intravenous Anesthesia.

*Table 1*. (Continued)

| Author/Year | Block investigated | Local anesthetic for Pecs block | Pain scores | Opioid consumption | Time to first analgesic requirement | Sensory block duration | Opioid related adverse effects | Patient satisfaction | Block-related complications |
|---|---|---|---|---|---|---|---|---|---|
| Bashandy *et al*., 2015 (13) | Pecs II | Bupivacaine 0.25%:<br>▪ PMm-Pmm: 10 mL<br>▪ Pmm-SA: 20 mL | ■ | ■ | | | ■ | | |
| ELdeen, 2015 (14) | Pecs II | Bupivacaine 0.5% with 0.5$\mu$g/mL dexmedatomidine:<br>▪ PMm-Pmm: 10 mL<br>▪ Pmm-SA: 20 mL | ■ | ■ | | ■ | | ■ | |
| Hassn *et al*., 2016 (20) | Pecs II | Dexmedetomidine-bupivacaine:<br>▪ PMm-Pmm: 10 mL<br>▪ Pmm-SA: 20 mL | ■ | ■ | ■ | | ■ | ■ | |
| Hetta *et al*., 2016 (18) | Pecs II without Pecs I | Bupivacaine 0.25%:<br>▪ Pmm-SA: 30 mL | ■ | ■ | ■ | | | | ■ |
| Kulhari *et al*., 2016 (19) | Pecs II | Ropivacaine 0.5%:<br>▪ PMm-Pmm: 10 mL<br>▪ Pmm-SA: 15 mL | ■ | ■ | | ■ | | | ■ |
| Morioka *et al*, 2015 (15) | Pecs II | Ropivacaine 0.25% or 0.375%; or levobupivacaine 0.25% or 0.5%:<br>▪ PMm-Pmm: 10-20 mL<br>▪ Pmm-SA: 20-40 mL | ■ | ■ | | | ■ | | |
| Sopena-Zubiria *et al*., 2014 (17) | Pecs I | Mepivacaine 1%:<br>▪ PMm-Pmm: 5 mL | ■ | ■ | | | ■ | | ■ |
| Wahba *et al*., 2013 (16)) | Pecs II | Levobupivacaine 0.25%:<br>▪ PMm-Pmm: 10 mL<br>▪ Pmm-SA: 20 mL | ■ | ■ | ■ | | ■ | ■ | ■ |

■ Outcome reported

Abbreviations: PMm indicates pectoralis major muscle; Pmm indicates pectoralis minor muscle; SA indicates serratus anterior muscle.

*Table 2.*
Study results of RCTs and cohort studies involving at least 10 participants per arm

| Author/ Year | Groups (n) | Peroperative pain scores | Postoperative pain scores | | | Peroperative opioid consumption | Postoperative opioid consumption | | | Time to first analgesic requirement | Sensory block duration | Opioid related adverse effects | | | Patient satisfaction | Results |
|---|---|---|---|---|---|---|---|---|---|---|---|---|---|---|---|---|
| | | | Early | Mid | Late | | Early | Mid | Late | | | PONV | Pruritus | Sedation | | |
| Bashandy *et al.*, 2015 (13) | - GA (60)<br>- GA with Pecs II block (60) | | + | + | | + | + | | | | | + | | + | | Significant lower pain scores were observed in the Pecs group. |
| ELdeen, 2015 (14) | - Thoracic spinal block (20)<br>- Pecs II block (20) | + | + | + | | | + | | | | + | | | | <--> | Pecs block reduces pain scores throughout surgery |
| Hassn *et al.*, 2016 (20) | - GA with placebo block (30)<br>- GA with Pecs II block (30) | | + | + | + | + | + | + | + | + | | + | | + | + | Pecs II block reduces postoperative and chronic pain as well as analgesics requirements. |
| Hetta *et al.*, 2016 (25) | - GA with paravertebral block (30)<br>- GA with Pecs II without Pecs I block (30) | | <--> | - | - | <--> | - | | | - | | | | | | Pecs II without Pecs I block provides inferior postoperative analgesia than the paravertebral block |
| Kulhari *et al.*, 2016 (19) | - GA with paravertebral block (20)<br>- GA with Pecs II block (20) | | + / <-->[#] | <--> | | <--> | + | | | | + | | | | | Pecs block provides superior postoperative analgesia than the paravertebral block |
| Morioka *et al,* 2015 (15) | - GA: TIVA (35)<br>- GA: TIVA with Pecs II block (36) | | + | | | + (Remifentanil) | <--> (Fentanyl) | | | | | <--> | | | | Pecs block reduces intraoperative remifentanil requirements and postoperative pain scores |
| Sopena-Zubiria *et al.*, 2014 (17) | - Deep sedation with paravertebral block (30)<br>- Deep sedation with Pecs I and paravertebral block (30) | | | + / <-->[§] | | <--> | +[A] | | | | | <--> | | | | Adding the Pecs I block to the paravertebral reduces pain scores in the first 8 hours after surgery |
| Wahba *et al.*, 2013 (16) | - Paravertebral block (30)<br>- Pecs II block (30) | | + | + / -[‡] | | + | + | + | + | + | | <--> | | | <--> | Pecs block reduces morphine consumed at 24 h |

Abbreviations: + indicates Pecs block favored; - indicates comparator favored; <--> indicates no difference identified; TIVA indicates total intravenous anesthesia.
[A] no p-value provided; # Pecs block favored during first 2 hrs., no difference identified after 2 hrs.; § Pecs block favored at 8 h, no difference identified at 24 h; † Pecs block favored at awakening, no difference identified at 1 h; ‡ Pecs block favored at 6 and 12 h, comparator favored at 18 and 24 h

qualitatively. The risk of bias was assessed by using the five-point Jadad score (6) for RCTs and by using the nine-point NOS (7) methodology for observational studies.

All other studies such as studies with less than 10 participants per arm, non-full articles (e.g., society abstracts), case series, case reports, special articles, letters to editors, editorials, expert reports and reviews were included in Group 2 and used to describe and discuss the techniques, review their indications, and identify any advantages or complications of these techniques. The quality of evidence was evaluated using the Oxford Center for Evidence-Based Medicine 2011 Levels of Evidence methodology (8).

This research has a holistic approach, hence we have included variations of the Pecs blocks techniques (9-12) in this review.

## Results

Figure 3 presents an overview of the search results following the PRISMA flow diagram. The records included in this review were supplemented by an additional eight publications that provide important background information related to the Pecs blocks or serve as reference of the applied methodology.

We identified eight studies which fulfill the criteria of Group 1 (13-20). Table 1 presents an overview of the study characteristics whereas Table 2 synthesizes the studies' results. These studies do not allow a viable and meaningful meta-analysis due to the limited number of trials, too diverse endpoints and/or endpoints reported on different time points or intervals.

### *Results from RCTs and large cohort studies*

**Pain scores and opioid consumption** - All eight studies (13-20) of Group 1 assessed the impact on pain scores and opioid consumption.

Three studies assessed the impact of Pecs II to a control group which did not receive a regional anesthesia technique (13,15,20). Two of these studies (13,15) analyzed the impact of adding the Pecs II block to GA. They both reported significantly lower postoperative pain scores, one during the first 24 hrs. (13) and the other during 48 hrs. (15) after surgery. Bashandy *et al*. (13) used significantly less intra-operative (115 *vs*. 252 µg fentanyl) and postoperative (2.9 *vs*. 6.9 mg morphine) opioids in their RCT. The cohort study of Morioka *et al*. (15) reported significantly less remifentanil (7.3 *vs*. 10.9 µg/kg/h) usage while consuming a comparable level of fentanyl (0 *vs*. 0.84 µg/kg/h) during surgery. The RCT of Hassn *et al*. (20) presents similar results: the authors showed that patients with a Pecs II block consumed significantly less intra-operative (107.76 *vs*. 150.83 µg fentanyl) and postoperative (15.9 vs. 4.7 mg morphine) opioids as compared to patients with a placebo block. Furthermore, patients reported consistently lower pain scores during the first 24 hrs after surgery, as well as during their 6 months follow-up.

Five studies compared the Pecs blocks to another regional anesthesia technique (14,16-19). Eldeen's RCT (14) compared the Pecs II to the thoracic spinal block and identified improved pain scores during and up to 24 hrs. after surgery, with decreased opioid needs, by using the Pecs II block (75.76 vs. 150.83 µg fentanyl).

Two studies compared the Pecs II block to the paravertebral block. The first RCT (16) examined the Pecs II for radical modified mastectomy and compared its analgesic performance to the paravertebral block by using the same type and concentration of local anesthetic agent. Patients receiving the Pecs II block required less perioperative opioids (intra-operative : 105 *vs*. 127 µg fentanyl; postoperative: 21 *vs*. 28 mg morphine) and reported lower pain scores during the first 12 hrs. after surgery, while patients receiving the paravertebral block reported lower pain scores during the following 12 hrs. The second RCT (19) had a comparable set-up and found that patients required significantly less opioids (3.90 *vs*. 5.30 mg morphine) during 24 hrs. after surgery, while pain levels were lower or comparable in the Pecs group. The authors did not find any difference in intra-operative opioid consumption, as none of the patients required additional fentanyl after the induction dose of 1 µg/kg.

Hetta *et al*. (18) compared the Pecs II without Pecs I block (one injection between the pectoralis minor and serratus anterior muscle) to the paravertebral block in patients undergoing unilateral modified radical mastectomy with axillary clearance. They found that comparable proportions required intraoperative fentanyl (20% *vs*. 23% of patients). The Pecs group consumed higher levels of opioids at 24-hrs. (20 *vs*. 12 mg morphine) postsurgical opioids. After comparable pain levels during the first 4 h, patients with the Pecs block reported significantly higher pain levels.

Finally, one study evaluated the effect of adding the Pecs I block to the paravertebral block (17). Patients who received both blocks required, compared to the paravertebral block alone, a

*Table 3.*
Overview of Pecs block's applications

| | Statement of evidence | RCT | Cohort study | Case series | Case report | Other[1] |
|---|---|---|---|---|---|---|
| **Pecs type I block** | | | | | | |
| • Breast expanders | 5 | | | | | + (2,3) |
| • Subpectoral prostheses | 4 | | | + (44) | + (45) | + (2,3) |
| • Traumatic chest injuries | 5 | | | | | + (3) |
| • Iatrogenic pectoral muscle dissections | 5 | | | | | + (3) |
| • Pacemaker, port-a-cath | 4 | | | + (46) | | + (3) |
| • Breast augmentation | 4 | | | + (47) | + (48) | |
| • Persistent pain after breast cancer surgery | 4 | | | + (26) | | |
| • Tumorectomy | 4 | | | + (21) | | |
| • Postoperative pain after mastectomy | 4 | | | + (49) | | |
| • Breast reductions | 4 | | | + (44) | | |
| • Mastectomy | 4 | | | + (44) | | |
| • Axillary node sampling | 4 | | | + (44) | | |
| • Chest drains | 5 | | | | | + (3) |
| • Reconstructive breast surgery | 2b | | (50,51) | | | |
| **Pecs type II block** | | | | | | |
| • Axillary clearance | 1b | + (13,16,52) | + (35,53) | | (54) | + (3) |
| • Wide excision | 5 | | | | | + (3) |
| • Tumorectomy | 1b | + (14,52) | + (35) | | | + (3) |
| • Sentinel node exeresis | 5 | + (52) | | | | + (3) |
| • Mastectomy | 1b | + (13,16,52,55,56) | + (15,35,40,53,57) | + (44,58) | + (25,54,59-64) | + (3) |
| • Partial rib resection | 2b | | + (39) | | | |
| • Lumpectomy | 5 | | | | + (61) | |

[1] Other includes expert/ brief technical reports and letters to the editors

comparable level of intra-operative opioids, though needed less postoperative opioids (no data provided) at 8 h after surgery. No statistically significant difference could be identified 24 h post surgery.

**Sensory block duration and time to first analgesic requirement** - Eldeen (14) and Kulhari *et al.* (19) respectively identified a significantly longer sensory block duration of the Pecs II block as compared the thoracic spinal block (994 *vs.* 382 min) and paravertebral block (294.5 *vs.* 197.5 min). Wabha *et al.* (16) and Hassn *et al.* (20) showed, respectively, that the time for first request of morphine was longer in their Pecs block group than their paravertebral block (175 vs. 137.5 min)

*Table 4*.
Overview of the Pecs blocks' applications in combination with other regional anesthesia techniques

| Surgery | Pecs block | Other block(s) | Level of evidence |
|---|---|---|---|
| Breast cancer surgery in myastentic patient | Pecs I | Paravertebral block | 5 (66) |
| Mastectomy with sentinel exeresis | Pecs I | Paravertebral block | 5 (67) |
| Polytrauma with multiple upper rib fractures | Pecs II | Serratus plane block | 5 (68) |
| Breast reduction plus mastopexy | Pecs II | Serratus plane block and anterior intercostal nerves block | 5 (69) |
| Modified radical mastectomy | Pecs I | Serratus plane block | 5 (70) |
| Mastectomy and reconstruction with breast expander | Pecs I | Serratus plane block | 5 (22) |
| Radical mastectomy and axillary dissection | Pecs I | Serratus plane block | 5 (71) |
| Intractable post thoracotomy syndrome | Pecs I | Serratus-intercostal plane block | 5 (72) |
| Breast conservation surgery with dissection of the axillary nodes followed by reconstruction using a latissimus dorsi pedicle flap | Pecs I | Serratus-intercostal plane block | 5 (73) |
| Pacemaker/automatic internal cardiac defibrillator insertion | Pecs II | Superficial cervical plexus block | 5 (74) |
| Mastectomy | Pecs I | Cutaneous branches of intercostal nerves block | 5 (75) |
| Cardiac resynchronization therapy device implantation | Pecs I | Intercostal nerve block | 5 (76) |
| Upper limb fistula surgery | Pecs II | Supraclavicular brachial plexus block | 5 (23) |
| Postoperative pain after reconstructive breast surgery | Pecs I | Serratus plane block and parasternal Pecs block | 5 (77) |
| Axillo-brachial arteriovenous graft creation surgery | Pecs II | Supraclavicular block | 5 (78) |
| Removal of infected breast implant | Pecs II | Parasternal block | 5 (79) |
| Unilateral modified radical mastectomy | Pecs II | Transversus thoracic muscle plane block | 1b (80) |

and placebo group (90.6 vs. 240.1 min). Finally, Hetta *et al*. (18) found that the postoperative time to first analgesic request was shorter in the group receiving pectoralis minor - serratus anterior block as compared to the paravertabral group (6 hrs. *vs*. 11 hrs.).

**Opioid-related adverse effects** - Postoperative nausea and vomiting (PONV) is the most studied opioid-related adverse effect. Three out of five studies did not identify any difference as compared to their control group (13,15-17,20). Bashandy *et al*. (13) noted a statistically significant improvement in PONV in the general anesthesia (GA) combined with Pecs groups as compared to the GA group using a 5-point PONV scale (0 indicates no nausea or vomiting and 4 indicates vomiting more than once) during their post anesthesia care unit stay (0.15 vs. 1.65). Hassn *et al*. (20) found a similar result by comparing the presence of PONV in the Pecs and placebo group (1/30 vs. 4/30 patients). Morioka *et al*. (15) assessed PONV based on the number of incidences, and did not find any difference when adding the Pecs block to total intravenous anesthesia (11.4% vs. 16.7%). The same metric was used by Wahba *et al*. (16) to compare their Pecs and paravertebral group. They concluded that PONV was comparable between both groups (53.3% vs. 56.7%). Finally, Sopena-Zubiria *et al*. concluded that adding a Pecs I block to the paravertebral block does not impact PONV (no data provided) (17).

Improved patient's sedation Ramsay scores (2.1 *vs*. 3.2) were identified in patients who had a

Pecs block as compared to those having GA alone (13). Also, one study found that less patients in the Pecs group had high postoperative sedation levels (Ramsay scores 5 or 6) (8/30 vs. 2/30) as compared to the placebo group (20).

**Patient satisfaction** - No difference in patient satisfaction could be identified between patients receiving a Pecs block and the thoracic spinal (75% *vs*. 70% patients satisfied) (14) or paravertebral block (0/9/13/8 *vs*. 0/9/14/7 ratings as respectively poor/fair/good/excellent satisfaction score counts) (16) on the other hand. A randomized controlled trial comparing the Pecs II block to a sham block did find a significant increase in patient satisfaction (22/30 *vs*. 13/30 satisfied patients) (20).

**Block-related complications** - Four studies explicitly reported not to have encountered any Pecs block-related complications (16-19).

**Clinical indication** - The eight larger studies reported successful use of the Pecs block for mastectomy (13,15,16,18-20), axillary clearance (18), conservative breast surgery (14) and breast surgery with subpectoral implants (17).

*Results from wider literature*

**Block-related complications** - In the collected literature, we did not found any studies focusing on block-related complications. Nevertheless, we also did not find any report on such complications. One study did report, while not hypothesizing on any causal link, two patients experiencing light paresthesia in one finger just after tumor surgery (21). Authors did note explicitly to not have encountered any complications from the Pecs blocks (22,23).

**Clinical indication** - The Pecs blocks have been successfully applied in a wide range of settings, both as the sole regional anesthesia technique (Table 3) as well as in combination with other blocks (Table 4).

While larger studies have focused on single shot techniques (13-20), the Pecs block was initially described to be used both as a single shot and continuous technique (2). Some authors have reported a successful use of the Pecs blocks with continuous infusion. (24,25)

Next to benefits in surgical settings, the Pecs blocks could offer additional benefits in pain medicine. In a pilot study with eight patients (26), the authors assessed - amongst other effects - pain interference with sleep in patients with persistent pain after breast cancer surgery for seven days starting on the day after they received the Pecs II block. The authors noted a significantly improved sleep quality in patients receiving the block. Another use of the Pecs blocks could be the management of chronic pain. Kim *et al*. (27) described two cases where the second injection of the Pecs II block resulted in adequate and durable analgesic effects for zoster-associated pain. Thottungal *et al*. (28) presented three pectoralis major syndrome cases where a combined Pecs II - serratus plane block resulted in highly effective pain relief. Finally, Ueshima *et al*. (29) reported that the Pecs II block was an effective treatment for the contraction of the latissimus dorsi muscle.

## Discussion

This qualitative systematic review suggests that our collective understanding of the Pecs blocks is limited, insofar as only six RCTs and two larger cohort studies related to the Pecs blocks have been published. In the absence of a homogenous and robust body of evidence, we argue that it is too premature to move from evidence to evidence-based clinical recommendations.

Current evidence does consistently indicate that adding the Pecs II block to the GA regimen diminishes the need for intra-operative and postoperative opioids in breast surgery, while reducing pain scores. When comparing the Pecs II block to the thoracic spinal and paravertebral block for breast surgery, the Pecs II block outperforms the traditional techniques up to 24 hrs. after surgery, in terms of postoperative pain scores and perioperative opioid consumption.

The Pecs blocks are described to be safe, superficial, and easy to perform (2,3) which seems to be confirmed by the absence of block-related complications reported in the literature.

Several arguments have been raised to sustain the ease of performing Pecs blocks. First of all, the Pecs block can be performed in patients who are fully awake or under general anesthesia (3,15). No sedation requirement for regional anesthesia simplifies the technique, by ruling out distraction of the anesthesiologists such as cooperation of the patient or cardiovascular and respiratory interventions (30). Second, the Pecs blocks are performed within superficial structures, which have clear ultrasound-visible landmarks (3). Next, the block can be performed under real-time ultrasound.

(16) Furthermore, the sites of injection for the Pecs blocks are outstretched interfascial planes (2,31), which are more easy to target than neurovascular bundles.

Some authors have identified potential unwanted side effects. Pérez *et al*. (11) noted that Pecs I block's coracoid level approach as described by Blanco *et al*. (2) could result in acromiothoracic artery injection or puncturing the cephalic vein or pleura. To reduce these risks, they suggest placing the ultrasound probe below the outer third of the clavicle, in the transverse plane, and introducing the needle in plane from medial to lateral. Additional potential side-effects associated with the Pecs II block include pneumothorax and axillary fascia puncture (4). Considering these potential risks, it is clear that the Pecs blocks should be performed under ultrasound guidance, and that the blocks should not be performed blind or based on landmark techniques (32-34).

The Pecs blocks are easy to learn techniques. (13,35) Additionally, given the fact that the Pecs blocks require less advanced technical skills and a short learning curve (18), they could lower the entry and indication barriers to the clinical usage of regional anesthesia for breast surgery. These are important benefits as a recent study in the North East of England concluded that the primary reason driving the underutilization of regional anesthesia for mastectomy is insufficient training (36). Likewise, a French nationwide study concluded that some anesthesiologists feel uncomfortable using more invasive regional anesthesia techniques such as the thoracic epidural and paravertebral block (37).

The Pecs blocks are suitable techniques for perioperative analgesia (2,3) and have demonstrated - next to their analgesic characteristics - favorable economic results. One study compared the mean time sparing for GA with sedation and a Pecs II block for breast surgery interventions (38). They reported that the second group required, on average, 10 min less time in the surgery room (11 vs. 21 min induction and awake time). Logically, this enables practices to offer more cost-effective medical care. Research teams also investigated the impact of adding the Pecs block to the anesthetic regimen on the length of stay after surgical decompression as a treatment for the thoracic outlet syndrome (39) and mastectomy (40). They identified a statistically significant reduction in postsurgical stay (respectively 2 *vs*. 3 days and 1 *vs*. 2 days). Both benefits require further formal investigation.

## Limitations

We acknowledge that this review has some limitations. First of all, results were assessed qualitatively, as current evidence does not allow a viable and meaningful meta-analysis. The quality of evidence of a systematic review with meta-analysis is always better than a qualitative systematic review. Next, the limited time between the initial description of the blocks and the start of the review (4-5 years) might limit the validity of the results, as large-scale, well-designed, prospective randomized controlled trials require significant time to prepare, execute, analyze, and publish. Nevertheless, as noted by Liu *et al*., (41) "adoption (...) often precedes the best evidence of benefit (...)". As one author already concluded in early 2015 that the Pecs block "(...) becomes more familiar nowadays among anesthetists compared to the paravertebral and thoracic epidural nerve blocks with breast surgery" (42), we could judge that our results likely reflect reality and that this limitation may only have minor impact on the results. Finally, while we were able to compare the efficacy of the Pecs blocks to some traditional techniques, there is a lack of comparison of the Pecs blocks with local anesthetic infiltration alone, which some authors consider to be standard practice. (43)

## Conclusion and future directions

In conclusion, the Pecs blocks challenge the conventional approach arguing that evidence leads to change in practice. Indeed, several practitioners have already incorporated these blocks in their practice before conclusive evidence regarding their efficacy and safety has been published.

Currently available results present encouraging evidence that the Pecs blocks provide effective analgesia and reduce postoperative opioid consumption. The Pecs blocks may provide favorable analgesic results in a wide range of clinical indications, not only for regional anesthesia, but also in chronic pain medicine. The blocks have shown favorable results as stand-alone techniques, in combination with GA or sedation and/or in combination with other regional anesthesia techniques. The absence of block-related complications reported in the literature could suggest that the Pecs blocks are safe techniques.

We also conclude that there is a pressing need for well-designed randomized controlled trials with placebo rather than active comparator to validate current evidence. We further suggest studies

comparing the Pecs blocks to local or wound infiltration, a formal evaluation of the various techniques to perform the Pecs blocks, and an assessment of the impact of volume, concentration, and type of local anesthetic agent used when performing the Pecs blocks in a dose-response study.

**Bibliography**


1 Wu CL, Raja SN. *Treatment of acute postoperative pain*. The Lancet, **377** : 2215-2225, 2011.
2 Blanco R. *The "pecs block": a novel technique for providing analgesia after breast surgery*. Anaesthesia, **66** : 847-848, 2011.
3 Blanco R, Fajardo M, Parras Maldonado T. *Ultrasound description of Pecs II (modified Pecs I): a novel approach to breast surgery*. Rev Esp Anestesiol Reanim, **59** : 470-475, 2012.
4 Bolin ED, Harvey NR, Wilson SH. *Regional Anesthesia for Breast Surgery: Techniques and Benefits*. Curr Anesthesiol Rep, **5** : 217-224, 2015.
5 Moher D, Liberati A, Tetzlaff J, Altman DG, Group P. *Preferred reporting items for systematic reviews and meta-analyses: the PRISMA statement*. Int J Surg, **8** : 336-341, 2010.
6 Jadad AR, Moore RA, Carroll D, Jenkinson C, Reynolds DJM, Gavaghan DJ, *et al*. *Assessing the quality of reports of randomized clinical trials: is blinding necessary?* Control Clin Trials, **17** : 1-12, 1996.
7 Wells GA, Shea B, O'connell D, Peterson JEA, Welch V, Losos M, *et al*. *The Newcastle-Ottawa Scale (NOS) for assessing the quality of nonrandomised studies in meta-analyses*, 2000.
8 OCEBM Levels of Evidence Working Group. The Oxford 2011 Levels of Evidence. Oxford Centre for Evidence-Based Medicine. 2011.http://www.cebm.net/index.aspx?o=5653 (accessed 29 Oct2016).
9 Blanco R. *PECS I+II: Indications and limitations*. Reg Anesth Pain Med, **39** : e89-e90, 2014.
10 Pérez MF, Duany O, de la Torre PA. *Redefining PECS Blocks for Postmastectomy Analgesia*. Reg Anesth Pain Med, **40** : 729-730, 2015.
11 Pérez MF, Miguel JG, de la Torre PA. *A new approach to pectoralis block*. Anaesthesia, **68** : 430-430, 2013.
12 Schuitemaker Requena JB, Mayoral Ripamonti JT, Sala Blanch X, Muñoz Pérez SL, López Pantaleon LA, Tintore Caicedo X, *et al*. *Proposal of a new anatomical approach for pectoral nerve block (PEC's block)*. Reg Anesth Pain Med, **40** : e191, 2015.
13 Bashandy GMN, Abbas DN. *Pectoral nerves I and II blocks in multimodal analgesia for breast cancer surgery: a randomized clinical trial*. Reg Anesth Pain Med, **40** : 68-74, 2015.
14 ELdeen HM. *Ultrasound guided pectoral nerve blockade versus thoracic spinal blockade for conservative breast surgery in cancer breast : A randomized controlled trial*. Egypt J Anaesth 2015.
15 Morioka H, Kamiya Y, Yoshida T, Baba H. *Pectoral nerve block combined with general anesthesia for breast cancer surgery: a retrospective comparison*. JA Clin Rep, **1** : 1-5, 2015.
16 Wahba SS, Kamal SM. *Thoracic paravertebral block versus pectoral nerve block for analgesia after breast surgery*. Egypt J Anaesth, **30** : 129-135, 2014.
17 Sopena-Zubiria LA, Fernández-Meré LA, Valdés Arias C, Muñoz González F, Sánchez Asheras J, Ibáñez Ernández C. *Thoracic paravertebral block compared to thoracic paravertebral block plus pectoral nerve block in reconstructive breast surgery*. Rev Esp Anestesiol Reanim, **59** : 12-17, 2012.
18 Hetta DF, Rezk KM. *Pectoralis-serratus interfascial plane block vs thoracic paravertebral block for unilateral radical mastectomy with axillary evacuation*. J Clin Anesth, **34** : 91-97, 2016.
19 Kulhari S Bharti N, Bala I, Arora S, Singh G. *Efficacy of pectoral nerve block versus thoracic paravertebral block for postoperative analgesia after radical mastectomy: a randomized controlled trial*. Br J Anaesth, **117** : 382-386, 2016.
20 Ali Hassn A, Zanfaly H, Biomy T. *Pre-emptive analgesia of ultrasound-guided pectoral nerve block II with dexmedetomidine-bupivacaine for controlling chronic pain after modified radical mastectomy*. Res Opin Anesth Intensive Care, **3**:6-13, 2016.
21 Soto PA, Luis JC, Bosser J, Poch P. Peripheral blocks for analgesia in breast cancer surgery: 8AP4-6. *Eur J Anaesthesiol EJA*, **31** : 137, 2014.
22 Petrucci E, Tullio P, Scimia P, Testa A, Paladini G, Marinangeli F, *et al*. *Is it possible to perform mastectomy and reconstruction with breast expander in a patient who refused general anesthesia? a case report*. Reg Anesth Pain Med, **40** : e172, 2015.
23 Purcell N, Wu D. *Novel use of the Pecs II block for upper limb fistula surgery*. Anaesthesia, **69** : 1294-1294, 2014.
24 Fajardo Pérez M, Cucchi C, Paniagua Montes MA, García Miguel J. *Bloqueo continuo de los nervios pectorales para cirugía de mama*. Rev Cir Mayor Ambulatoria, **16** : 191-2, 2011.
25 Sá M, Cardoso M, Gouveia A, Barroco I. *Continuous "PECs" block as an analgesic alternative in unilateral simple mastectomy*. Reg Anesth Pain Med, **40** : e158, 2015.
26 Wijayasinghe N, Andersen KG, Kehlet H. *Analgesic and Sensory Effects of the Pecs Local Anesthetic Block in Patients with Persistent Pain after Breast Cancer Surgery: A Pilot Study*. Pain Pract, n/a-n/a., 2016
27 Kim Y-D, Park S-J, Shim J, Kim H. *Clinical usefulness of pectoral nerve block for the management of zoster-associated pain: case reports and technical description*. J Anesth, 1-4, 2016.
28 Thottungal A. *Pecs block and serratus plane block under ultrasound-a novel approach to treat pectoralis major syndrome-an under diagnosed cause for chronic anterior chest wall pain*. Reg Anesth Pain Med, **41** : e115, 2016.
29 Ueshima H, Otake H. *Pectoral nerves block for a contraction of the latissimus dorsi muscle*. J Clin Anesth, **31** : 200, 2016.
30 Tobias JD, Leder M. *Procedural sedation: A review of sedative agents, monitoring, and management of complications*. Saudi J Anaesth, **5** : 395-410, 2011.
31 Blanco R. T*he "pecs block": A novel technique for providing analgesia after breast surgery*. Anaesthesia, **66** : 847-848, 2011.
32 Nair AS, Sahoo RK, Ganapathy M, Mudunuri R. *Ultrasound guided blocks for surgeries/procedures involving chest wall (Pecs 1, 2 and serratus plane block)*. Anaesth Pain Intensive Care, **19** : 348-351, 2015.
33 Abrahams M, Derby R, Horn J-L. *Update on Ultrasound for Truncal Blocks: A Review of the Evidence*. Reg Anesth Pain Med, **41** : 275-288, 2016.
34 Fajardo Pérez M, Blanco Davila R, García Miguel FJ. *El bloqueo de los nervios pectorales guiado por ultrasonidos puede ser de utilidad en la cirugía de mama reconstructiva para control del dolor postoperatorio*. Rev Esp Anestesiol Reanim, **59** : 578-580, 2012.
35 Versyck B, Van Houwe P. *Learnings from large-scale application of the PECS block: an alternative to the*

*paravertebral block in breast cancer surgery*. In: *39th Annual Regional Anesthesiology and Acute Pain Medicine Meeting*.Chicago, Illinois, USA: ASRA, 2014.

36 Womack J, Varma M, Callaghan M. *A survey of use of regional anaesthesia for mastectomy in the North East of England*. Reg Anesth Pain Med, **40** : e144, 2015.

37 Dualé C, Gayraud G, Taheri H, Bastien O, Schoeffler P. *A French Nationwide Survey on Anesthesiologist-Perceived Barriers to the Use of Epidural and Paravertebral Block in Thoracic Surgery*. J Cardiothorac Vasc Anesth Published Online First: 11 November 2014. doi:10.1053/j.jvca.2014.11.006

38 Bajocco C, D'Ettorre M, Araosta F, Iovino G, Tavoletta S, Cianchetti E, *et al*. *Regional against general anesthesia in breast surgery: the importance of being earnest*. Reg Anesth Pain Med, **39** : e156, 2014.

39 Meyns J, Coppens S, Van de Velde M. *A new approach for postoperative pain control after surgical decompression as treatment for thoracic outlet syndrome: the pecs block*. Churchill Livingstone, 2015. pp. e100-e100.

40 Pakkar-Hull A, Kant A, Lain H. *Pecs block for mastectomy: Does it make a difference to hospital stay? A retrospective studyata district general hospital*. Reg Anesth Pain Med, **41** : e69, 2016.

41 Liu SS, Ngeow JE, Yadeau JT. *Ultrasound-guided regional anesthesia and analgesia: a qualitative systematic review*. Reg Anesth Pain Med, **34** : 47-59, 2009.

42 Sedra R. *Pectoralis Minor Nerve Block versus Thoracic Epidural and Paravertebral Block in Perioperative Pain Control of Breast Surgery-Mini Review*. Enliven J Anesth Crit Care Med, **2** : 009, 2015.

43 Turbitt L, Nelligan K, McCartney C. *Pectoral Nerve Blocks for Breast Cancer Surgery: A Methodological Evaluation*. Reg Anesth Pain Med, **40** : 388-389, 2015.

44 Mehrotra S, Kuttambakam H, Nair R, Rudner J, Emamdee R. *Pecs block as part of a morphine sparing anaesthetic technique for breast surgery: Initial results*. Reg Anesth Pain Med, **38** : E229, 2013.

45 Haydon NB, van der Rijt R, Downs C, Buckland G. A *Novel Technique of Intraoperative Lateral Pectoral Nerve Block During Subpectoral Breast Implant Placement*, Plast Reconstr Surg - Glob Open, **4** : e646, 2016.

46 Johnson M, Doyle Y, McNeill D, McGinley J. *A case series of pectoralis blocks in the paediatric cath lab; a novel technique for post operative analgesia*. Reg Anesth Pain Med, **40** : e196, 2015.

47 Quiceno I, Rubio J, Carvajal J. *Pec block, a new tool: Combine ideal outcomes for surgeon, anesthesiologist and patient*. Reg Anesth Pain Med, **40** : e141, 2015.

48 Leiman D, Barlow M, Carpin K, Piña EM, Casso D. *Medial and Lateral Pectoral Nerve Block with Liposomal Bupivacaine for the Management of Postsurgical Pain after Submuscular Breast Augmentation*, Plast Reconstr Surg Glob Open, **2** : e282, 2014.

49 Wallaert M, Courivaud P, Mati E-H, Shiniara M, Guilbert J-M. *Bloc interpectoral avec mise en place d'un cathéter pour analgésie postopératoire après chirurgie mammaire*. Ann Fr Anesth Réanimation, **3** : 269-271, 2014.

50 Sacadura Orvalho C, Pedrosa F, Rodrigues I. *PECS block as a post-operative analgesic strategy for reconstructive breast surgery: Preliminary results*. Reg Anesth Pain Med, **41** : e71, 2016.

51 Blanco R, García MG, García PD, Nebril BA, Álvarez SL. *Eficacia analgésica del bloqueo de los nervios pectorales en cirugía*. Rev Cir Mayor Ambulatoria, **16**:89-93, 2011.

52 Versyck B, Van Houwe P, Van Geffen GJ. *Prospective double blind randomized placebo-controlled clinical trial of the pectoral nerves block type II*. Reg Anesth Pain Med, **41** : e77, 2016.

53 Kanitkar R, Mane A, Agashe A, Kulkarni M, Deshmukh S. *Modified pectoral nerves block for postoperative analgesia after modified radical mastectomy: A comparative study (abstract)*. *Cancer Res* 2016. In : *Proceedings of the Thirty-Eighth Annual CTRC-AACR San Antonio Breast Cancer Symposium*: 2015 Dec 8-12; San Antonio, TX. Philadelphia (PA), AACR, Abstract nr P2-12-13.

54 Yano K, Ijiri E, Satoh M, Izumi Y, Iida T, Sasakawa T, *et al*. *Anesthetic management in a patient with respiratory complication undergoing mastectomy using PECSII block and dexmedetomidine: A case report*. Reg Anesth Pain Med, **41** : e144-e145, 2016.

55 Giordano C, Scimia P, Basso Ricci E, Fusco P, Mondello E, Danelli G. *Pecs block vs thoracic paravertebral block for the management of postoperative analgesia in major breast surgery: Preliminary findings*. Reg Anesth Pain Med, **41** : e94, 2016.

56 Lykoudi E, Delistathis G, Stavropoulou E, Tselempis E, Oikonomou E, Mpournavea S, *et al*. *Pectoral nerves I and II blocks for breast cancer surgery*. Reg Anesth Pain Med, **41** : e63, 2016.

57 Morioka H, Kamiya Y, Yoshida T, Takamatsu M, Baba H. *Efficacy of PECS block for perioperative pain management in breast cancer surgery*. Reg Anesth Pain Med, **39** : e155, 2014.

58 Amir A, Jolin S, Amberg S, Nordstrom S. *Implementation of Pecs I and Pecs II Blocks as Part of Opioid-Sparing Approach to Breast Surgery*. Reg Anesth Pain Med, **41** : 544-545, 2016.

59 Phoon HYP, Tay CYW, Ng O, Chan XHD. *The role of modified pectoral nerves (PECS) block in bilateral simple mastectomy*. Reg Anesth Pain Med, **39** : e171, 2014.

60 Fusco P, Testa A, Petrucci E, Scimia P, Bafile A, Pozone T, *et al*. *Can bilateral pecs ii block provide a good quality of anesthesia and a very long lasting analgesia after bilateral mastectomy? a case report*. Reg Anesth Pain Med, **40** : e78, 2015.

61 Murata H, Ichinomiya T, Hara T. *Pecs block for anesthesia in breast surgery of the elderly*. J Anesth, **29** : 644-644, 2015.

62 Petrucci E, Fusco P, Scimia P, Luciani A, Danelli G, Pozone T, *et al*. *Ultrasound-guided PECS II block in a high-anesthetic risk patient case report*. Reg Anesth Pain Med, **40** : e156, 2015.

63 Doyle Y, Jonhson M, Hickey C, Conlon N, Geraghty. *The use of PECS blocks as the sole anaesthetic technique for total mastectomy*. Reg Anesth Pain Med, **41** : e137, 2016.

64 Fusco P, Paladini G, Scimia P, Petrucci E, Luciani A, Vacca F, *et al*. *To block or not to block. This is the question*. Reg Anesth Pain Med, **41** : e140, 2016.

65 Saura Henriques DSC, Inácio R, Susano MJ, Prosil Sampaio J, Mourão Rodrigues MI. *"PECS II block" for breast surgery combined anesthesia-case report*. Reg Anesth Pain Med, **41** : e141-e142, 2016.

66 Li N-L, Chen Y-J. *Paravertebral block combined with pectoral nerve block for a myasthenic patient undergoing breast cancer surgery*. Research, **1**. doi:10.13070/rs.en.1.728, 2014.

67 Díaz A, Ledesma B, Gilsanz F. *Bloqueo paravertebral torácico, más bloqueo de nervios pectorales para mastectomía en un paciente con esclerosis lateral amiotrófica avanzada*. Rev Esp Anestesiol Reanim, **61** : 172-173, 2014.

68 Arunachalam S, Townsley P, Bedforth N. *Pecs and Serratus plane block for chest wall analgesia in multiple rib fractures*. Anaesthesia, **69** : 11, 2014.

69 Arteaga Mejía D, Schuitemaker Requena JB, Mayoral Ripamonti JT, Sala-Blanch X, Tintoré Caicedo X, Brasó Vicen C. *Pec II block (PEC) and serratus plane block*

*(SPB). Are they useful in breast surgery?* Reg Anesth Pain Med, **39** : e294, 2014.

70 Bouzinac A, Brenier G, Dao M, Delbos A. *Bilateral association of pecs I block and serratus plane block for postoperative analgesia after double modified radical mastectomy*. Minerva Anestesiol, **81** : 589-590., 2015

71 Fusco P, Scimia P, Marinangeli F, Pozone T, Ucci EP. *The association betweentheultrasoundguided Serratus Plane Block and PECS i Block can represent a valid alternative to conventional anesthesia in breast surgery in a seriously ill patient*. Minerva Anestesiol, **82** : 241-242, 2016.

72 Fujiwara S, Komasawa N, Minami T. *Pectral nerve blocks and serratus-intercostal plane block for intractable postthoracotomy syndrome*. J Clin Anesth, **27** : 275-276, 2015.

73 Khemka R, Chakraborty A, Ahmed R, Datta T, Agarwal S. *Ultrasound-Guided Serratus Anterior Plane Block in Breast Reconstruction Surgery,* Case Rep, **6** : 280-282, 2016.

74 Golbaba B, Robards C, James C. *Combined superficial cervical plexus and "pecs block" for pace maker/ automatic internal cardiac defibrillator insertion*. Reg Anesth Pain Med, **38**, 2013.

75 Ortiz De La Tabla R, Martínez Navas A, Gómez Reja P, Sánchez Martín I, Sánchez Brotons MJ, Echevarría Moreno M. *Combined pectoral and cutaneous branches of intercostals nerves blocks in a high risk patient for mastectomy*. Reg Anesth Pain Med, **9** : e199, 2014.

76 Fujiwara A, Komasawa N, Minami T. *Pectoral nerves (PECS) and intercostal nerve block for cardiac resynchronization therapy device implantation*. Springer Plus, **3** : 409, 2014.

77 Hansen CK, Dam M, Poulsen TD, Lönnqvist P-A, Bendtsen TF, Børglum J. *Ultrasound-guided parasternal Pecs block: a new and useful supplement to Pecs I and serratus anterior plane blocks*. Anaesthesia Cases, 2016.

78 Tan YR, Quek KHY. *Tackling the axillary blind spot with PECS II*. Anaesthesia, **70** : 230-231, 2015.

79 Fusco P, Paladini G, Petrucci E, Scimia P, Vacca F, Tonelli E, *et al*. *PECS block and parasternal block in a patient with recent ischemic stroke*. Reg Anesth Pain Med, **41** : e139-e140, 2016.

80 Hironobu U, Hiroshi O. *Combination of pectoral nerves block and transversus thoracic muscle plane block provide effective perioperative pain relief for breast cancer surgery-a randomized clinical trial*. Reg Anesth Pain Med, **41** : e77, 2016.